

# Common Problems with the Mediolateral Oblique: How to Help Your Technologist

## Part 1 – The Inframammary Fold: How to Improve Visualization and Reduce Skin/Fat Folds in the Inframammary Fold

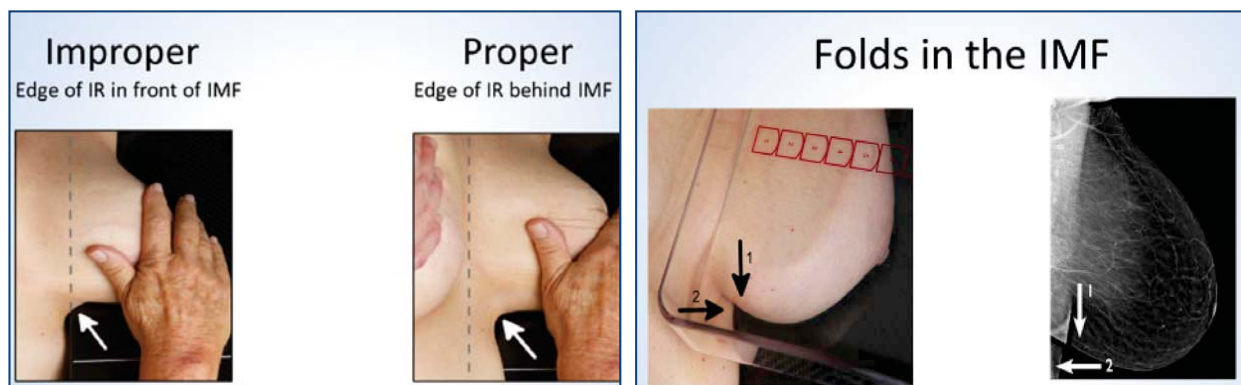
By Louise C. Miller, RTRM

This is the first of a 3-part article on how to provide feedback to your technologists regarding solutions to common positioning problems.

Please note that regardless of the experience and expertise of the technologist, the “perfect” image cannot be produced 100% of the time. Remember the last time you were selecting images for American College of Radiology accreditation? I am sure, like most radiologists, you reviewed seemingly hundreds of images to find the “perfect” case for submission. Even so, we all are a bit anxious waiting for the results. When the data regarding positioning criteria were published in 1993,<sup>1</sup> the authors stated that even after receiving hands-on, standardized positioning training for acquiring a mediolateral oblique (MLO), visualization of the inframammary fold (IMF) was obtainable only 49% of the time. This outcome was largely due to variations in body habitus and other patient issues. Interestingly, there have been no published articles with current data considering the change in image receptor (IR) and face shield width and length, thus making positioning the MLO even more challenging. Data recently collected by an academic breast imaging department, but not yet published, demonstrate that updated standardized techniques significantly increase visualization of the IMF. The remainder of this article will discuss specific methods to improve IMF imaging.



Louise C. Miller, RTRM



**Figure 1.** Proper positioning is achieved by lifting the breast and bringing the IMF (arrow) onto the image receptor. The dashed line indicates the edge of the IR. Source: *Mammography Positioning Guidebook*, by Louise Miller, RTRM. Reprinted with the permission of the author.

**Figure 2.** Horizontal fold is in the medial breast (1). Vertical fold is in the lateral breast (2). Source: *Mammography Positioning Guidebook*, by Louise Miller, RTRM. Reprinted with the permission of the author.

## ◀ ***Common Problems with the Mediolateral Oblique: How to Help Your Technologist, continued from previous page***

---

### **Methods for Increasing Visualization of the IMF**

The position of the patient relative to the bottom front corner of the IR is critical (Figure 1):

- The patient must be facing forward, towards the mammography machine.
- The lower front corner of the IR should be directly below the patient's nipple and halfway between her anterior-superior iliac spine and umbilicus.
- This positioning requires the patient to step towards the technologist, who should be standing at the medial side of the breast to be imaged.

### **Methods for Reducing Skin Folds in the IMF**

Bassett's study showed that skin and fat folds were present on approximately 15% of MLO images.<sup>1</sup> Skin folds were more prominent on full-field digital mammography (FFDM) because of the digital algorithm and increased width of the IR. It is virtually impossible to exclude all skin and fat folds on every image. It is interesting to note that following updated standardized positioning training for FFDM and digital breast tomosynthesis (DBT), which includes increased visualization of posterior breast tissue, the number of skin and fat folds *increased*.

Horizontal folds in the IMF usually occur in the medial breast and are difficult for the technologist to see when positioning the patient (Figure 2). Corrective actions can include the following:

- Make sure that the breast is held in the up-and-out position.
- The up-and-out position should be maintained until compression is complete.
- Have the patient lift her contralateral breast up and back without pulling ipsilateral breast tissue out from under the compression paddle.

Vertical folds in the IMF usually occur in the lateral side of the breast and are difficult for technologists to see when positioning the patient as that area of the breast is hidden from view by the IR. Corrective action can include the following:

- Make sure to smooth lateral and inferior breast tissue before lifting the breast up and out from the chest wall.
- Check for position of the IMF (see above). Pulling too much lateral breast tissue in front of the IR will cause additional folds in this area. ❖

### **REFERENCE**

1. Bassett LW, Hirbawi IA, DeBruhl, N, Hayes MK. Mammographic positioning: evaluation from the view box. *Radiology*. 1993;188(3):803-806.