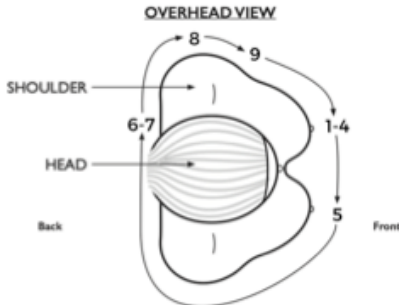


## CC QUICK STEPS

The following steps should be performed after the proper compression paddle size is chosen, machine is at 0 degree angulation and the patient is facing the machine with feet, hips and shoulders forward and level. The patient should be standing back about 2" from the IR with her nipple centered to the IR (or as close as possible). **Stand on the medial side** of the breast to be imaged. Steps below describe positioning for the LCC.

- \_\_\_ 1. Elevate breast/IMF (until the PNL is perpendicular to the chest wall)
- \_\_\_ 2. Adjust IR height (so top edge is parallel with elevated IMF)
- \_\_\_ 3. Pull breast onto IR with both hands (left hand on top; right hand on bottom). At the same time ask the patient to step forward into the machine (not to lean in) and have her turn her face towards you
- \_\_\_ 4. Anchor breast with the base of your right thumb (after switching hands)
- \_\_\_ 5. Lift the other breast onto IR with your left index finger in the IMF against the rib cage and your left thumb on the top of the breast and ask the patient to turn her right hip forward
- \_\_\_ 6. Guide the patient's head forward and around the face shield, if possible
- \_\_\_ 7. Place your left elbow and forearm at the mid thoracic region (where her bra clasp would be) and gently push the patient forward
- \_\_\_ 8. Relax her left shoulder with your left hand
- \_\_\_ 9. Pull superior breast tissue forward, if possible, then apply compression while continuing to "push" the patient forward and pulling





## The Miller Method™

### **IMAGE CHECKLIST FOR THE CC** ***Self-evaluation***

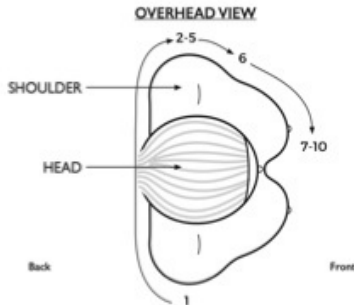
In order to ensure maximum inclusion of breast tissue, the technologist and radiologist should consider the following criteria:

- \_\_\_ Visualization of central, subareolar and medial aspects of the breast.
  
- \_\_\_ Visualization of pectoral muscle on approximately 40% of cases.
  
- \_\_\_ PNL must measure within 1.0 cm of PNL measurement on the MLO.
  
- \_\_\_ Retroglandular fat is visualized behind glandular breast tissue.

## MLO QUICK STEPS

The following steps should be performed after choosing the proper compression paddle is chosen and shifted (as needed), the proper degree of angulation is chosen and the IR lowered (as needed). The patient is facing the machine with both feet, hips and shoulders forward. The patient must move medially (towards you) so that the bottom of the IR is directly below the plane of the nipple (halfway between the ASIS and umbilicus). You should be standing on the medial side of the breast to be imaged. Steps below describe positioning for the LMLO.

- \_\_\_ 1. Stand perpendicular to the patient
- \_\_\_ 2. Lift patient's left shoulder/arm up over the corner of the IR with your left hand in the patient's axilla. At the same time, your right hand should "meet" your left hand in the axilla and help to lift the patient's left shoulder up and over the IR
- \_\_\_ 3. IR is placed in back of axilla (just inferior to latissimus dorsi)
- \_\_\_ 4. Patient's left hand should be resting on bar, with their elbow bent behind the IR
- \_\_\_ 5. Place your left hand on patient's left shoulder
- \_\_\_ 6. Your right-hand slides down lateral side of breast to pull on lateral breast tissue and smooth out any skin folds
- \_\_\_ 7. Once your right hand is at the bottom of the breast, turn your hand over so that your hand is now palm down on the breast with the base of your thumb just anterior to the IMF
- \_\_\_ 8. Push the breast up and out with the base of your thumb
- \_\_\_ 9. At the same, ask the patient to lift and flatten their other breast. Caution: Do not ask the patient to pull their breast back
- \_\_\_ 10. Continue to hold the breast in the up and out position until compression is complete





## The Miller Method™

### **IMAGE CHECKLIST FOR THE MLO** ***Self-evaluation***

In order to ensure maximum inclusion of breast tissue, the technologist and radiologist should consider the following criteria:

- \_\_\_ Visualization of all breast tissue within the perimeter of breast margins.
  
- \_\_\_ The position of the breast is supported up and away from the thorax (not drooping) and as close to perpendicular to the chest wall as possible.
  
- \_\_\_ Retromammary fat is visualized.
  
- \_\_\_ Inframammary fold is visualized and open.
  
- \_\_\_ Nipple is in profile.
  
- \_\_\_ Visualization of pectoral muscle: from axilla down to the level of the PNL, wide margin at axilla, convex or straight configuration and radiolucent appearance.