Dense Breasts: Imaging, Masking and Risk

Robin Seitzman, PhD, MPH
Director of Education and Epidemiology Research
DenseBreast-info.org

Mammography Reduces Deaths due to Breast Cancer

- **BUT, not all women benefit equally**
- Let's talk about what you need to know about dense breasts and the screening and risk implications of dense breast tissue

What are Dense Breasts?

- Dense tissue:

Glands and fibrous tissue ("fibroglandular" tissue)

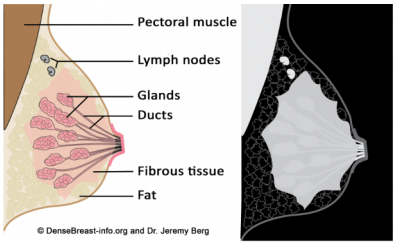

Why Does Breast Density Matter?

- Can mask cancer detection on mammography
  - False reassurance from a negative mammogram
  - More advanced stage at diagnosis
  - Consider supplemental screening in addition to MMG
- Increased risk of developing cancer
- Higher risk of death from breast cancer

How is Breast Density Determined?

- Breast density is usually determined by a radiologist's visual evaluation of the mammogram
- Other methods to determine breast density:
  - From mammograms by computer software
  - Computed tomography (CT scan) and MRI imaging
- Breast density cannot be determined by the way breasts look or feel

What Categories Are Used to Describe Breast Density on a Mammogram?

(A) Fatty; (B) Scattered fibroglandular density; (C) Heterogeneously dense; (D) Extremely dense

(Sickles EA et al., BI-RADS 5th edition, ACR, 2013; Sprague BL et al JNCI 2014)

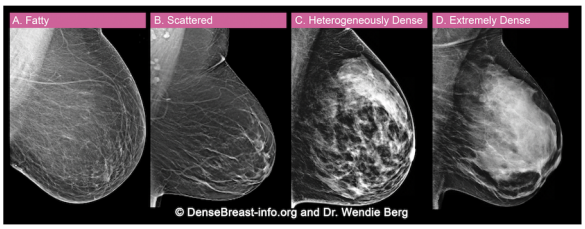

Which Categories of Breast Density are Considered "Dense Breasts?"

(C) Heterogeneously dense and (D) Extremely dense

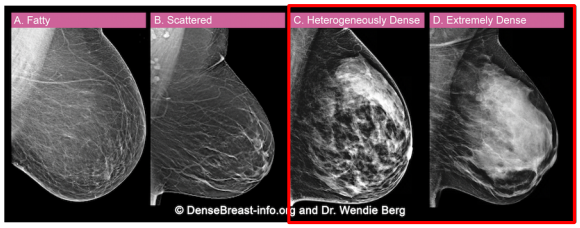

Masking: Dense Tissue Can Hide Cancer

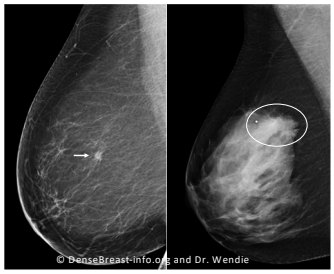

Are Dense Breasts a Disease? Are They Common? Should I Worry?

Dense breasts are normal.

MORE THAN **50%** of women under 50

40% of women in their 50s

25% of women 60 and over

© DenseBreast-info, Inc.

Why Does Breast Density Matter on a Mammogram?

- Dense breast tissue can hide cancer on a mammogram ➡ reduce effectiveness of mammography screening
- As breast density increases, the ability to see cancer on mammography decreases
- In women with dense breasts:
  - Negative or benign mammogram ≠ no cancer
  - Additional screening beyond mammography should be considered

Four Breasts With Cancer

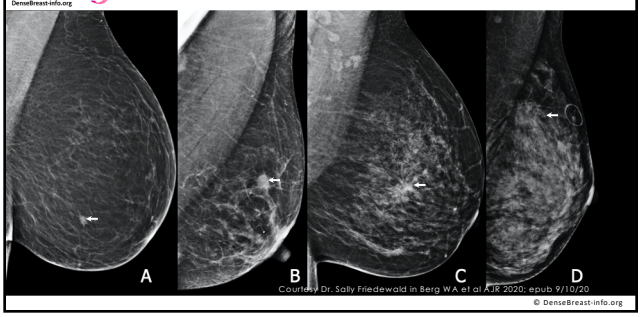

Courtesy Dr. Sally Friedewald in Berg WA et al AJR 2020; epub 9/10/20

The denser the breast, the more likely a cancer will be masked

Category of Breast Density	Percent of Cancers That Will Not Show on a Mammogram
Extremely dense	40%
Heterogeneously dense	25%
Scattered fibroglandular	15%
Fatty breasts	10%

© DenseBreast-info.org
Rev. March 2022

Wanders et al., Breast Cancer Res, 2017; Destounis et al., AJR, 2017; Kerlikowske et al., Ann Intern Med, 2015

Value of Mammography in Dense Breasts

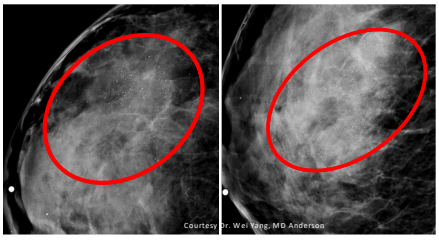

48F with suspicious calcifications, dense breasts; extensive high grade DCIS with microinvasion, ER/PR(-), HER2(+)

Invasive Lobular Carcinoma Likely to be Missed on Mammography

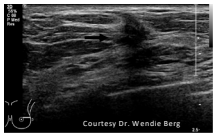

Routine annual screening MMG in 77-year-old woman

Heterogeneously dense breasts, asymmetries, negative

Screening US shows small irregular mass = 1.3 cm ILC, N0

Supplemental Screening Should Not Replace Mammography

- Supplemental screening in women with dense breasts should be done as an adjunct – not a replacement for mammography in women with dense breasts
  - Exception: high-risk women < age 30, MRI alone is recommended. Add annual mammography to annual MRI at age 30+ (same visit or alternating 6-month intervals)

Dense Breasts and Mammography Callbacks

- Average overall mammography callback rate = 10%
- Women with dense breasts are more likely to be called back for additional testing than are women with fatty breasts
- The vast majority (about 95%) of callbacks for additional imaging will not show cancer (false positive)
- The denser the breast, the more likely a false positive is to occur

McCarthy et al., JNCI 2014; Lehman et al., AJR 1999

Dense Breasts and Interval Cancers

- Interval cancers are those found due to symptoms before the next screen
- Odds of interval cancer increase with increasing density
- Women with extremely dense breasts have 13 to 18 times greater odds of experiencing an interval cancer than women with fatty breasts
- Interval vs. screen-detected cancers
  - More aggressive
  - Worse outcomes

Boyd et al., N Engl J Med 2007; Ciatto et al., Br J Cancer 2004

Cancers in Dense Breasts

- Outcomes in dense breasts differ from those in fatty breasts:
  - Greater risk of interval cancer
  - More often advanced stage (IIb and III)
  - More often multifocal or multicentric
  - Mastectomy more often needed for treatment
  - Greater risk of recurrence in women with history of breast cancer (especially if no radiation therapy is given)

Arora et al., Ann Surg Oncol 2010

Increased Risk of Developing Breast Cancer

Breast Cancer Risk by BI-RADS Breast Density Category

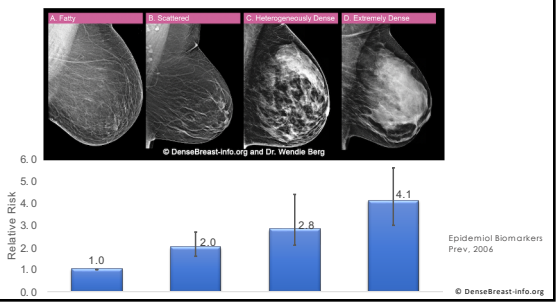

How Does Density Compare to Other Risk Factors?

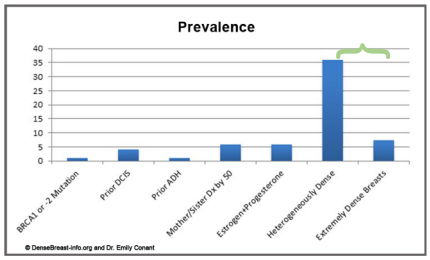

© DenseBreast-info.org

Similar Magnitude of Risk as Atypical Biopsy

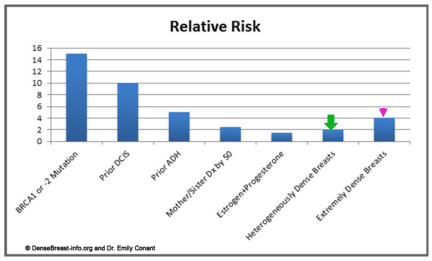

© DenseBreast-info.org

Population Attributable Risk

- More breast cancers can be attributed to dense breasts than family hx (1st-degree relatives), hx of benign bx, BMI (≥ 25), nulliparity, or late first birth (≥ 30)
  - 39% of premenopausal and 26% of postmenopausal breast cancer attributed to dense breasts

Engmann NJ et al JAMA Onc 2017 epub Feb 2, 2017

© DenseBreast-info.org

Glandular Tissue/Breast Cancer Risk Relationship

- The more glandular the breast tissue, the greater the breast cancer risk
  - Cancers arise microscopically in glandular tissue: the more glandular tissue, the more susceptible tissue where cancer can develop
    - Glands divide with hormonal stimulation; "mistakes" possible with each division
  - Local environment around glands may produce growth hormones that stimulate cell division. More common in fibrous than fatty breast tissue.

© DenseBreast-info.org

Breast Cancer Risk Factors

- Most women who develop breast cancer have no additional risk factors other than being female and aging.

Supplemental Screening

- ► Tomosynthesis ("3D"), now becoming standard of care instead of 2D mammography
- ► Ultrasound
- ► Molecular breast imaging (MBI)
- ► Contrast-enhanced digital mammography (CEDM)
- ► MRI

Expected Added Cancer Detection and change in false positive recall rates after Standard Mammography by Screening Modality

Method	Breast Density	Added Cancer Detection (from 2D 2-7 per 1000)	Projected change in False Positive Recall Rate (from 2D 100-120 per 1000)
Tomosynthesis (3D mammography)[1]	Scattered fibroglandular density or Heterogeneously dense	1-2 per 1000 [3-5]	-15 to -44 per 1000[c] [3-5]
Tomosynthesis (3D mammography)[2]	Extremely dense	Negligible [3, 8, 9]	No significant reduction [3, 8, 9]
Ultrasound (first round)[a]	Heterogeneously or Extremely dense	2-3 per 1000 [10]	+75 to 117 per 1000 [10, 11]
Ultrasound (subsequent rounds)	Heterogeneously or Extremely dense	3-4 per 1000 [11, 12]	+70 to 98 per 1000 [11, 12]
Ultrasound after tomosynthesis	Heterogeneously or Extremely dense	2-3 per 1000 [15, 16]	Increase in false positive recalls with US[a]
MBI	Heterogenously or Extremely dense	7-9 per 1000 [17-19]	+54 to 77 per 1000 [17-19]
Contrast-Enhanced Mammography	Heterogeneously or Extremely dense	8-13 per 1000 [20, 21]	+34 to 144 per 1000[c] [20, 21]
MRI (first round)	Extremely dense	16 per 1000 [22]	+80 per 1000 [22]
MRI (subsequent rounds)	Extremely dense	6 per 1000 [23]	+26 per 1000 [23]
Abbreviated ("fast" or "mini") MRI after tomosynthesis[c]	Heterogeneously or Extremely dense	10 per 1000 [24]	+107 per 1000 [24]

Reference available at http://densebreast-info.org/screening-technologies/cancer-detection-by-screening-method/

High-Risk Women Should Have Screening MRI Regardless of Breast Density

- Known or disease-causing mutation in *BRCA1/2* or other disease-causing mutation in patient or in 1st degree relative if patient untested
- Chest/mantle radiation therapy by age 30 and at least 8 years prior
- Personal history of breast cancer and dense breasts OR diagnosed by age 50
- Calculated lifetime risk of ≥ 20-25% by risk models based largely on family history
- History of LCIS/ADH on prior biopsy [consider MRI]

Screening for Dense Breasts and not Otherwise High Risk

For a woman with extremely dense breasts and not otherwise at increased breast cancer risk:

- ► Screening MRI in addition to mammogram/tomosynthesis
- ► If MRI not an option, consider ultrasound or contrast-enhanced mammography
- ► Same considerations for heterogeneously dense breasts; however, capacity may be limited
- ► Abbreviated MRI protocols may address barriers

51-year-old with Extremely Dense Breasts and Right Breast Pain

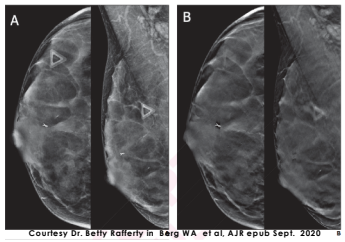

Courtesy Dr. Betty Kafferty in Berg WA et al, AJR epub Sept. 2020

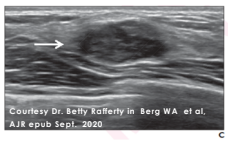

Courtesy Dr. Betty Kafferty in Berg WA et al, AJR epub Sept. 2020

40F with Lump Noted After Fall on Bicycle

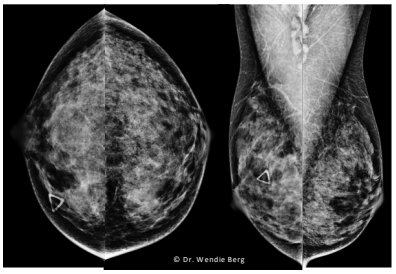

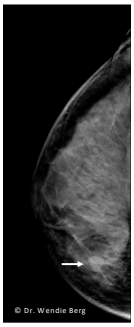

Ultrasound

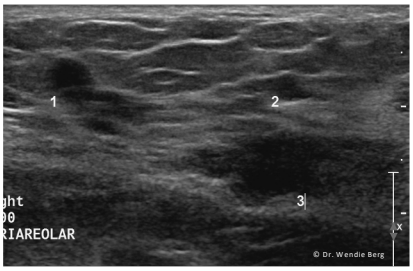

Sagittal Post-Contrast MRI

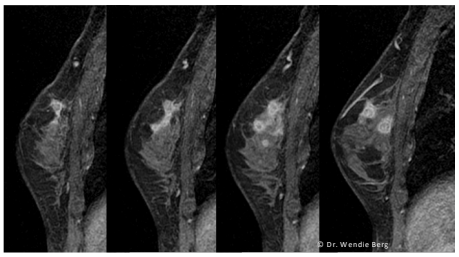

Patient Resources

What's Required in Your State?

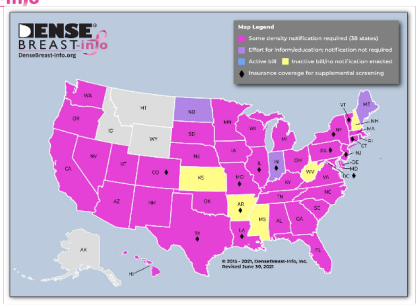

Medically-sourced Website
DenseBreast-info.org

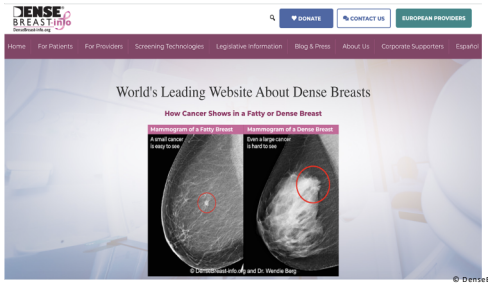

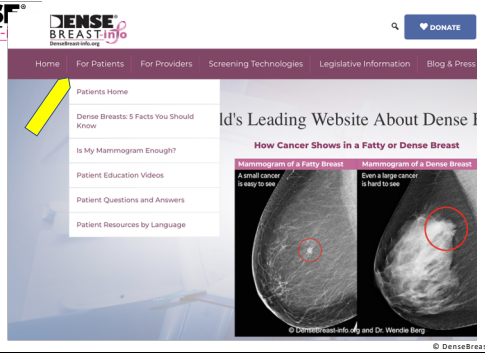

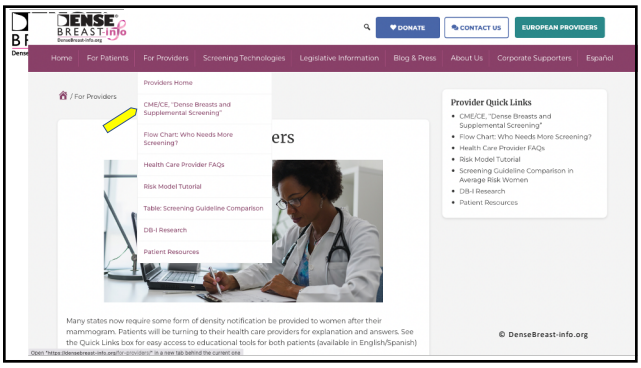

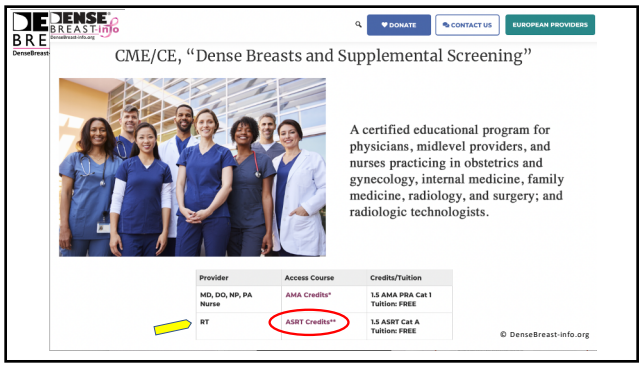

For more information, please visit:

Dense Breasts: Imaging Masking and Risk

Louise C. Miller, R.T.(R)(M)(ARRT), CRT, FSBI, FNCBC
Director of Education
Mammography Educators
www.mammographyeducators.com

Why is Image Quality So Important for Dense Breasts

- Abnormalities are more difficult to visualize
- More superimposition of structures
- Often more difficult to position
- Often more difficult to compress

Easy Peasy

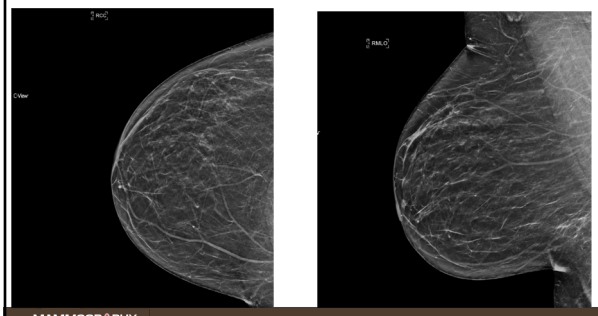

Hide-a-truck Breast

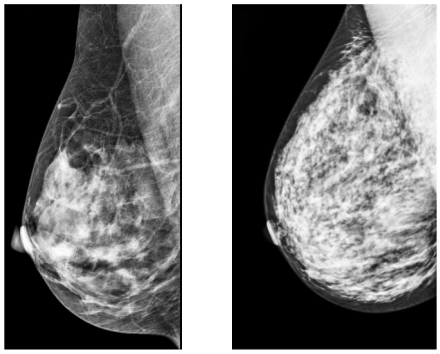

Anatomy of the Breast

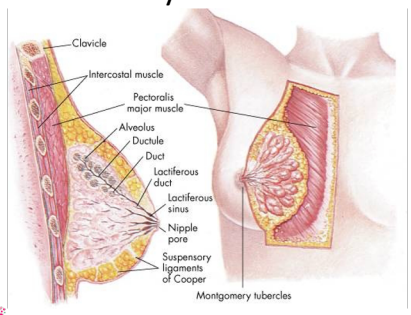

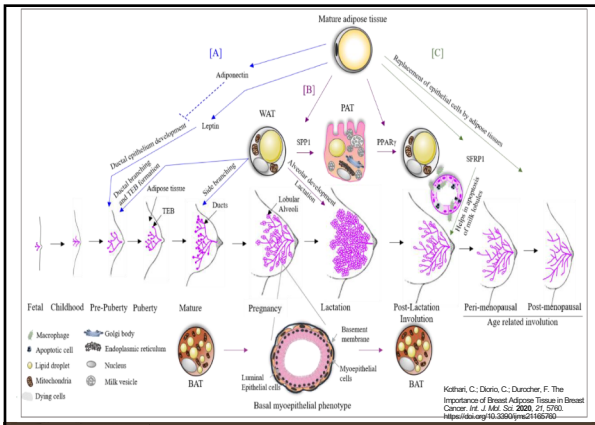

Kothari, C.; Diorio, C.; Durocher, F. The Importance of Breast Adipose Tissue in Breast Cancer. *Int. J Mol. Sci.* **2020**, *21*, 5760. https://doi.org/10.3390/ijms21165760

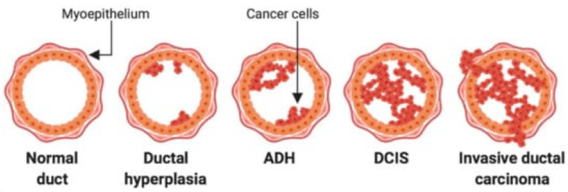

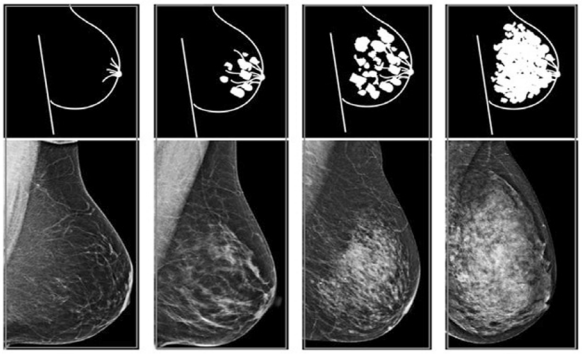

Use of Hormone Replacement Therapy

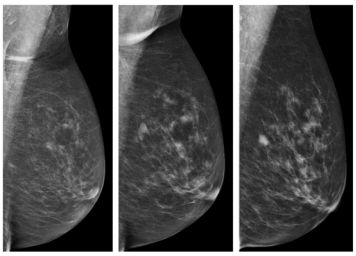

Where's Waldo







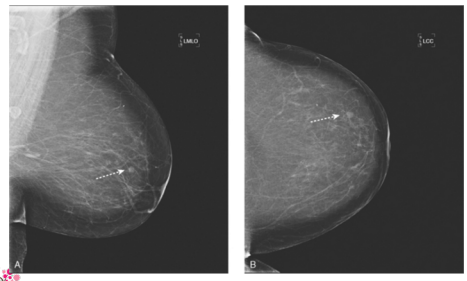

Positioning Challenges

- Penetration of glandular breast tissue
- Immobility
- Equal Compression
- Visualization of posterior glandular breast tissue
- Use of additional views

Penetration of Glandular Breast Tissue (Historically)

- Hot light
- Crank up the kVp
- Long exposure times

Hot Lights!



Turn the Knobs!

Crank up the kVp

Increase the time.

Thank You Modern Technology!!

ANCIENT HISTORY

FFDM - DBT

Photocell Placement



Positioning Challenges

- Penetration of glandular breast tissue
- **Immobility**
- Equal Compression
- Visualization of posterior glandular breast tissue
- Use of additional views

Immobility = Increased Skin Folds and Missed Breast Tissue

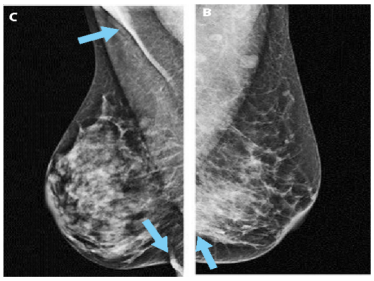

Positioning Challenges

- Penetration of glandular breast tissue
- Immobility
- **Equal Compression**
- Visualization of posterior glandular breast tissue
- Use of additional views

Compression to Separate Structures

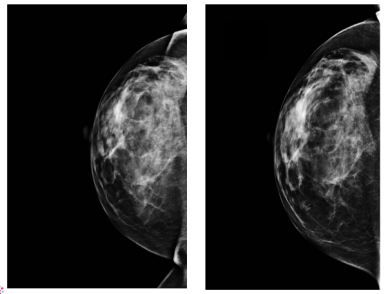

Compression

Criteria:

Breast should be compressed until taut or less than painful. Glandular tissue should be well separated.

Compression to Separate Structures

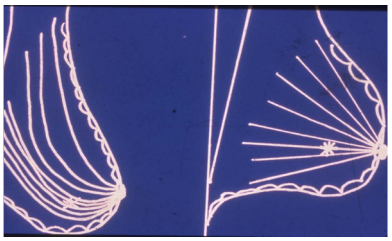

Drooping Breast

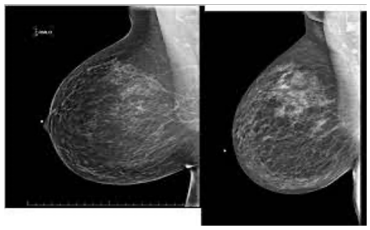

Drooping Breast

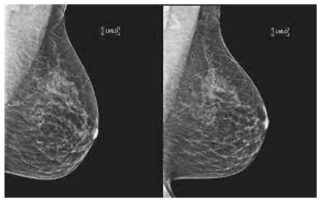

Positioning Challenges

- Penetration of glandular breast tissue
- Immobility
- Equal Compression
- **Visualization of posterior glandular breast tissue**
- **Use of additional views**

PNL Measurements

The measurement of the PNL on one view should be no less than 1 cm when comparing view to view

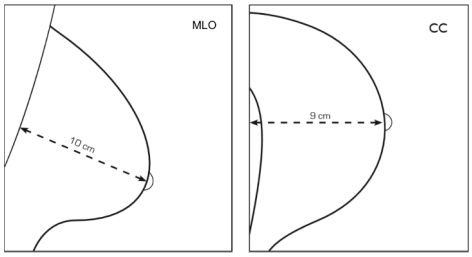

PNL + 1cm

Before After

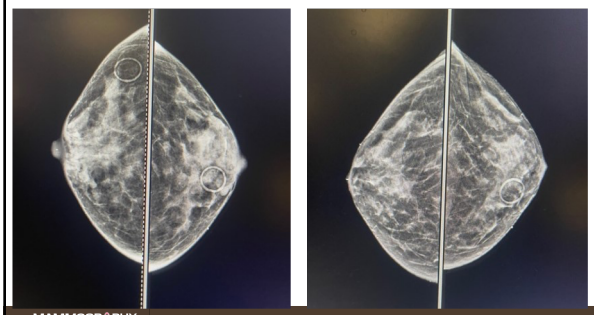

Before After

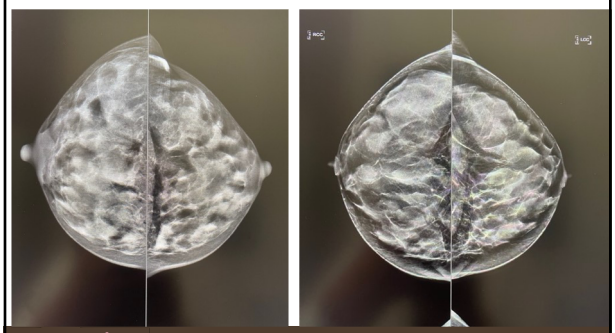

Before After

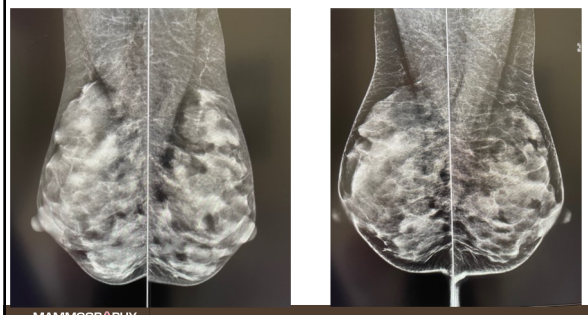

XCCLS

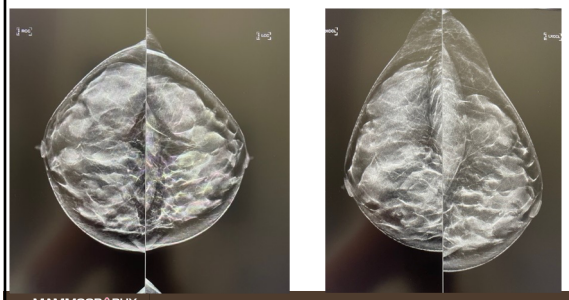

XCCL

- For visualization of lateral breast tissue in a CC projection
- Used on baseline mammogram when lateral, posterior glandular breast tissue is not visualized on the CC view
- On subsequent exams if the glandular breast tissue is visualized back to the retromammary fat space on the MLO and XCCL does not need to be performed.

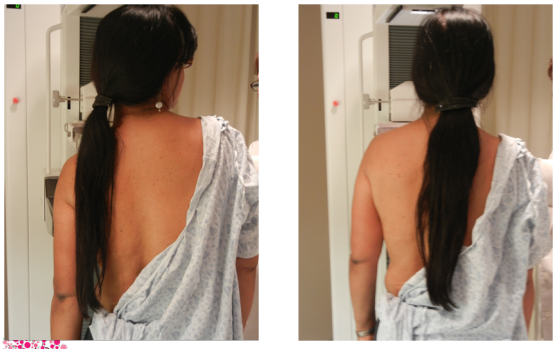

Use of the XCCL

- Should be performed on less than 10% of all patients
- No angling the tube: Performed at 0 degrees angulation
- No angling the patient: Patient's body should straight but turned at 45 degree angle to the IR
- Nipple should be pointing towards the upper corner of the image receptor

Visualization of pectoralis muscle is NOT preferable as it may indicate patient was leaning to the side. Direction of the beam should be superior to inferior *or* inferior to superior. It is NOT a less steep MLO

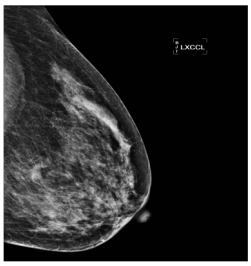

Summary

- Mammography image quality if even more important for women with dense breasts
- Positioning techniques are important to include posterior breast tissue
- Proper compression is critical to separate structures in the breast
- Patients with dense breasts have options

Thank you!

For questions or more information, contact us at:

www.mammographyeducators.com
619-663-8269
info@mammographyeducators.com

Services we offer include:

- Onsite Positioning Training
- Assistance with Accreditation & Inspections
- Live Webinars
- Customized Continuing Education Programs