Additional Mammographic Views

Louise C. Miller, R.T.(R)(M)(ARRT), CRT, FSBI, FNCBC
Director of Education
www.mammographyeducators.com

MAMMOGRAPHY EDUCATORS

1

Additional Views Lexicon – Labeling Codes

- XCCL - Exaggerated craniocaudal lateral
- CV – Cleavage
- ML - Mediolateral
- LM - Lateromedial
- AT - Axillary tail
- TAN - Tangential

MAMMOGRAPHY EDUCATORS

2

Additional Views Lexicon

- RL - Rolled lateral
- RM - Rolled medial
- RS - Rolled superior
- RI - Rolled inferior
- FB - Caudocranial

MAMMOGRAPHY EDUCATORS

3

Additional Views Lexicon

- SIO - Superior lateral to inferior medial oblique
- LMO - Lateromedial oblique
- M - Magnification
- ID - Implant displaced
- No label: Spot Compression

MAMMOGRAPHY EDUCATORS

4

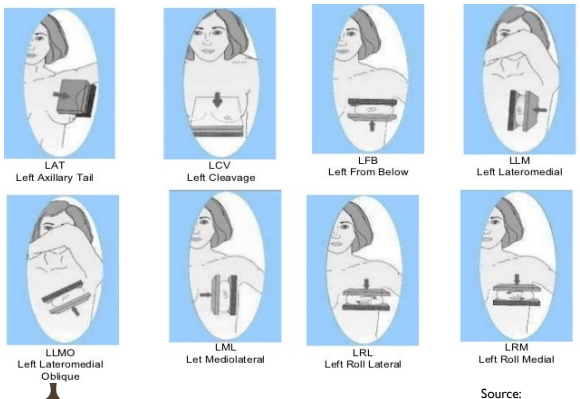

Source:

MAMMOGRAPHY EDUCATORS

5

Labeling codes (Lexicon)

- The name is view (Labeling code) is always preceded by identification of laterality.

i.e. LXCCL or RXCCL
LFB or RFB

MAMMOGRAPHY EDUCATORS

6

The Most Commonly Used Additional Views

- XCCL
- CV
- LM/ML

7

Why do we do additional views?

- To show a specific component of the anatomy not seen on standard views
- To provide localization of an area of concern medial/lateral or superior/inferior to the nipple

8

OR…

- To show an area of concern in better detail
- To counteract superimposition of structures
- To triangulate a lesion

9

Commonly used additional views are done to show a specific component of the anatomy not seen on standard views.

10

Ask and Answer

- Which part of the breast do I want to visualize?
- In which projection?
- Which view will accomplish this?

11

Imaging the Breast in a Transverse or Axial Plane

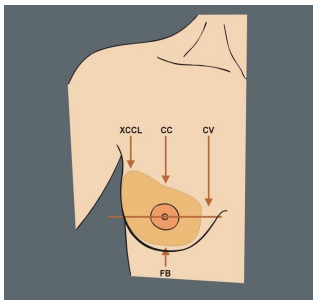

12

XCCL - Exaggerated CC Lateral

Visualization of lateral breast tissue in a CC projection

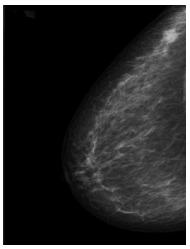

MAMMOGRAPHY EDUCATORS

13

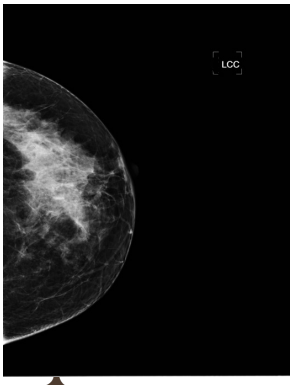

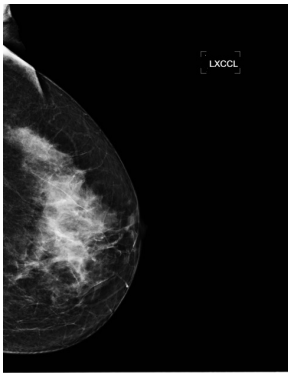

MAMMOGRAPHY EDUCATORS

14

Use of the XCCL

- Should be used on a baseline exam when lateral posterior breast tissue is missing on the CC view
- If glandular breast tissue on subsequent screening views is visualized back to the retromammary fat space on the MLO, an XCCL is not needed

MAMMOGRAPHY EDUCATORS

15

Use of the XCCL

- Should be performed <u>on less than 10%</u> of all patients
- Performed at 0 degrees angulation
- Patient's body should be at 45 degree angle to the IR
- Nipple should be pointing towards the upper corner of the image receptor

MAMMOGRAPHY EDUCATORS

16

Muscle or NO muscle?

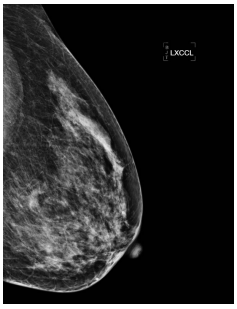

MAMMOGRAPHY EDUCATORS

17

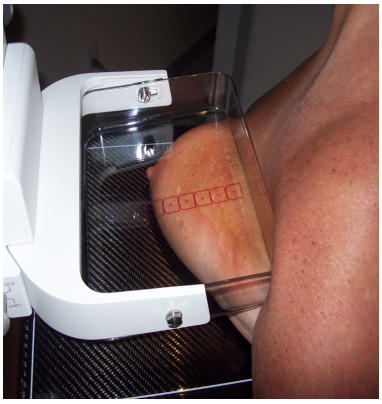

MAMMOGRAPHY EDUCATORS

18

Incorrect

Correct

MAMMOGRAPHY EDUCATORS

19

CV - Cleavage

For visualization of medial breast tissue in a CC projection

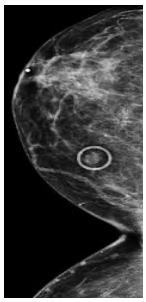

MAMMOGRAPHY EDUCATORS

20

Sternalis Muscle

MAMMOGRAPHY EDUCATORS

21

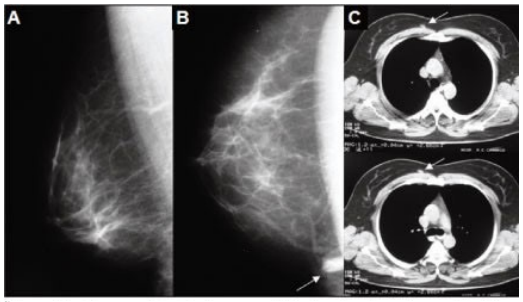

MAMMOGRAPHY EDUCATORS

22

Sternalis Muscle

- Flame-like appearance (similar to an appendix)
- Present in only 7-10% of the population
- Seen medially on a mammogram
- Often misdiagnosed as the insertion of the pectoralis muscle

MAMMOGRAPHY EDUCATORS

23

MAMMOGRAPHY EDUCATORS

24

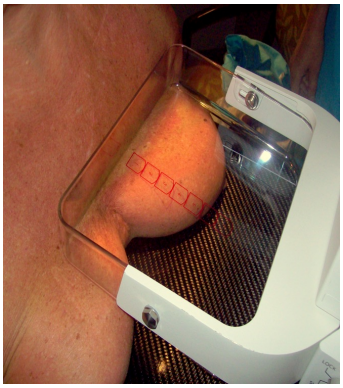

25

Medial or Lateral Orientation to the Nipple

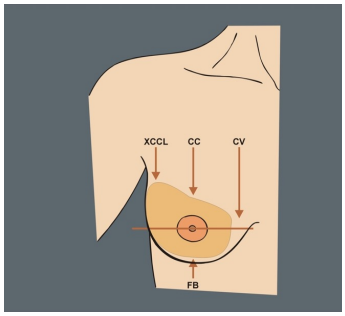

26

Axillary Tail

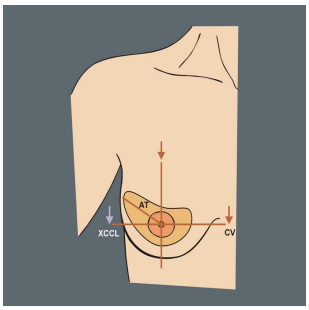

27

AT – Axillary Tail

- Angle tube to axillary tail
- Approximately 30 degrees

28

AT – Axillary Tail

It is never used to localize a lesion

29

AT – Axillary Tail

- The AT View is used only for focal compression of the axillary tail
- Anterior to posterior orientation and compression

30

AT – Axillary Tail

- It will not give you true lateral or medial or true superior or inferior orientation to the nipple

31

Axillary Tail

32

90-degree (true) lateral

- LM - Lateromedial
- ML - Mediolateral

33

Superior or Inferior Orientation to the Nipple (LM or ML)

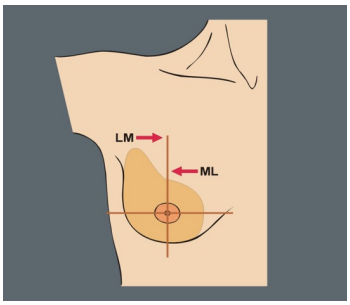

34

Use of the Lateral

- Shows effects of gravity on air fluid levels (Milk of Calcium)
- Used as a "tie breaker" view (to overcome superimposition of structure)
- Visualizes the breast in the sagittal plane (demonstrates an area of concern superior or inferior to the nipple)

35

Why Do the LM?

- When you did the MLO, you showed the lateral breast in better detail. The LM shows the medial breast in better detail.
- The LM takes advantage of the lateral mobile border of the breast and thus facilitates positioning.

36

Why Do the LM?

- The posterior medial breast is hardest part of the breast to image and the area most often missed on the MLO. If done properly, by off-setting the IR into the contralateral breast, you will be able to get deeper against the chest wall.

MAMMOGRAPHY EDUCATORS

37

Why Do the LM?

- There is no issue of the contralateral breast impeding the path of the compression paddle

MAMMOGRAPHY EDUCATORS

38

Improperly positioned LM with breasts separated so the middle of the IR is centered on midsternal line. This excludes deep medial breast tissue on the side you are imaging.

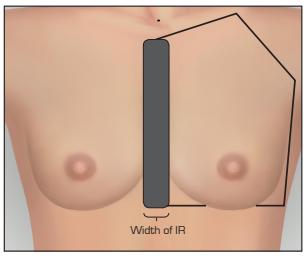

MAMMOGRAPHY EDUCATORS

39

Properly positioned LM with breasts separated so the *top edge of the IR* is centered on midsternal line and the width of the IR pressing against the contralateral breast.

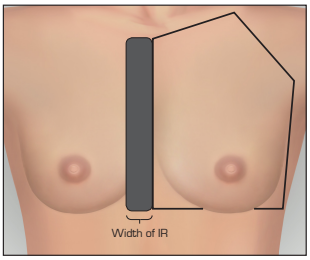

MAMMOGRAPHY EDUCATORS

40

ML – Mediolateral

The opposite breast must be pulled back to allow the compression paddle to pass and may therefore eliminate visualization of deep medial breast tissue.

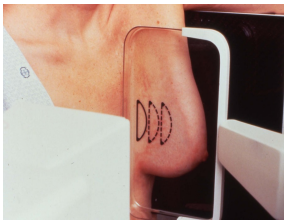

MAMMOGRAPHY EDUCATORS

41

Additional Views to Facilitate Imaging of Difficult Body Habitus

- LMO
- FB

MAMMOGRAPHY EDUCATORS

42

LMO – Lateromedial Oblique
FB – Caudocranial (From Below)

- Used when a standard MLO or CC is impossible
- Kyphotic patients
- Males with prominent pectoral muscles

43

LMO – Lateromedial Oblique

- Degree of angulation should be 90 degrees plus or minus the standard degree of angulation.
- Average 45-degree RMLO would be 135 degrees for RLMO

44

MLO

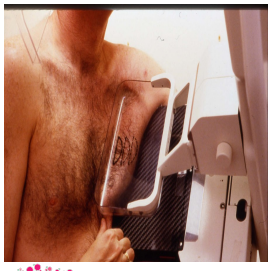

LMO

45

FB - Caudocranial

- Machine is turned 180 degrees opposite the CC
- Direction of the beam is Caudal to Cranial

46

CC

FB

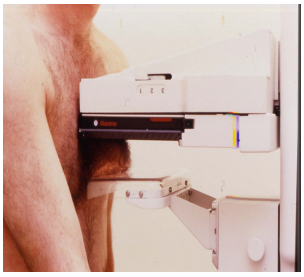

47

Additional Views for Clarification of Areas of Concern

- TAN
- Spot compression
- Spot compression with MAG
- Rolled views

48

TAN – Tangential View

- To prove the existence of dermal calcifications
- Enhanced visualization of palpable masses that may otherwise be superimposed on glandular breast tissue

MAMMOGRAPHY EDUCATORS

49

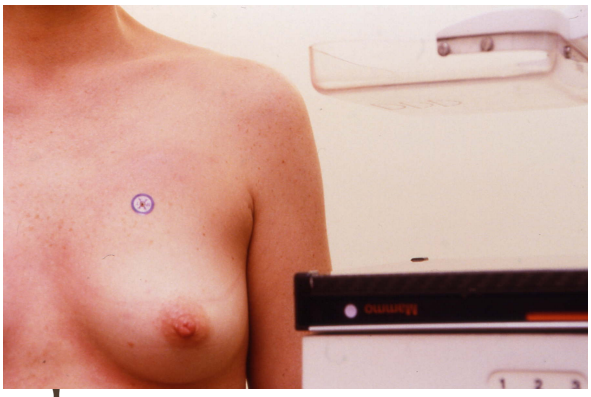

MAMMOGRAPHY EDUCATORS

50

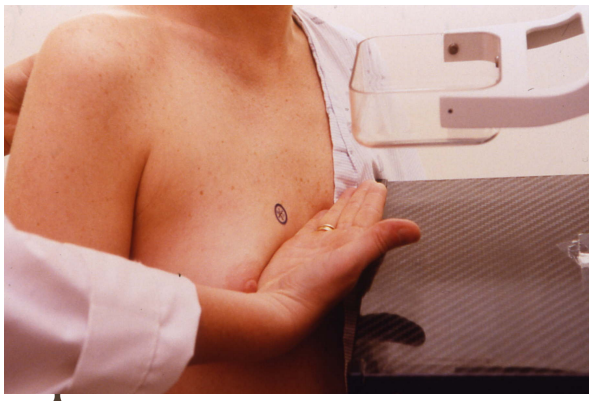

MAMMOGRAPHY EDUCATORS

51

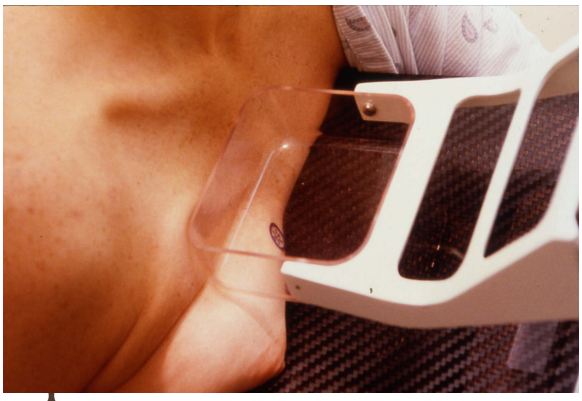

MAMMOGRAPHY EDUCATORS

52

Localization for Verification of Skin Calcifications

- Decreased with use of DBT
- Set up as the same as a needle localization
- Determine which quadrant the calcifications are located

MAMMOGRAPHY EDUCATORS

53

Localization for Verification of Skin Calcifications

- Use biopsy paddle
- Select direction of approach so that the window of biopsy paddle is closest to the area in question

MAMMOGRAPHY EDUCATORS

54

Tangential Views for the Verification of Skin Calcifications

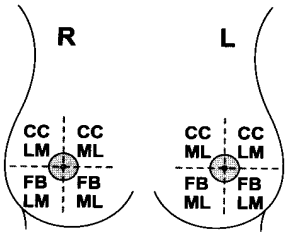

55

Tangential Views for the Verification of Skin Calcifications

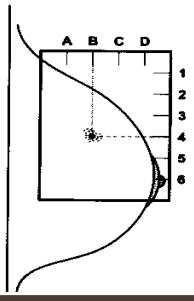

56

Tangential Views for the Verification of Skin Calcifications

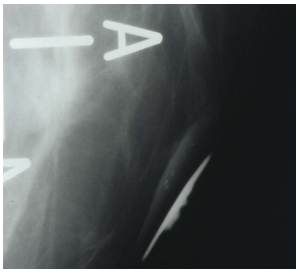

57

Spot Compression With/Without Magnification



58

All Would be Labeled LTAN

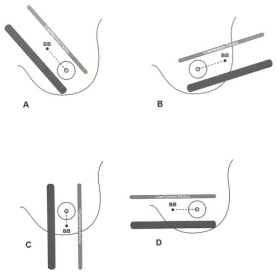

59

Spot Compression Paddles



60

Square vs Round Paddle

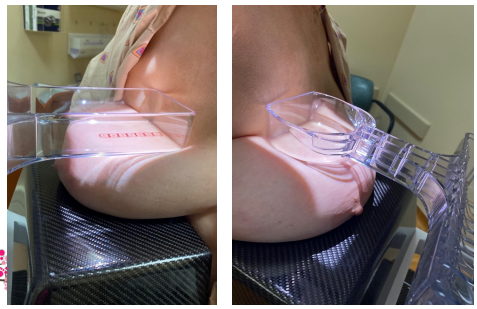

MAMMOGRAPHY EDUCATORS

61

Spot Compression with Magnification

MAMMOGRAPHY EDUCATORS

62

Square vs Round Paddle

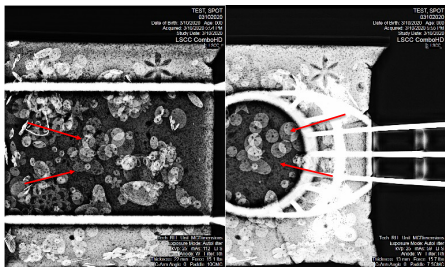

MAMMOGRAPHY EDUCATORS

63

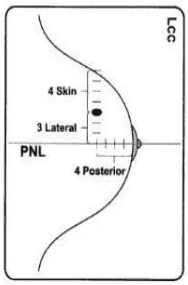

Spot/Mag Measurements

RIGHT LEFT

CC MLO LM ML

4 POSTERIOR / ANTERIOR ____

3 MED / LAT SUP / INF ____

4 SKIN ____

MAMMOGRAPHY EDUCATORS

64

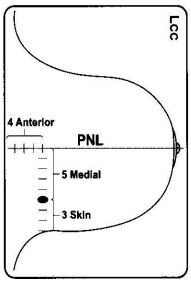

Spot/Mag Measurements

RIGHT LEFT

CC MLO LM ML

____ POSTERIOR / ANTERIOR 4

5 MED / LAT SUP / INF ____

3 SKIN ____

MAMMOGRAPHY EDUCATORS

65

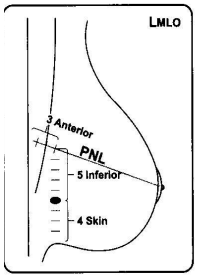

Spot/Mag Measurements

RIGHT LEFT

CC MLO LM ML

____ POSTERIOR / ANTERIOR 3

____ MED / LAT SUP / INF 5

____ SKIN 4

MAMMOGRAPHY EDUCATORS

66

Remember

- You must simulate compression when making measurements on the breast.
- Mark the center of the target area with a surgical marker so you can make appropriate corrections on subsequent images, if needed.

MAMMOGRAPHY EDUCATORS

67

Views Used To

- Overcome superimposition of structures by changing the orientation of the beam to the breast – **Roll views**
- Overcome superimposition of structures by changing the orientation of the breast to the beam – **Lateral views**

MAMMOGRAPHY EDUCATORS

68

Rolled Views

- RCCRM – Right CC superior breast rolled medial
- RCCRL – Right CC superior breast rolled lateral

MAMMOGRAPHY EDUCATORS

69

LCCRM – Left CC Rolled Medial

MAMMOGRAPHY EDUCATORS

70

Lateral Used To Overcome Superimposition

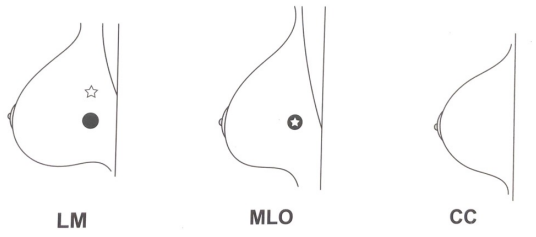

MAMMOGRAPHY EDUCATORS

71

Lateral Used For Lesion Location

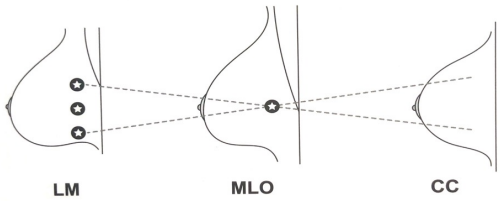

MAMMOGRAPHY EDUCATORS

72

Roll View to Overcome Superimposition

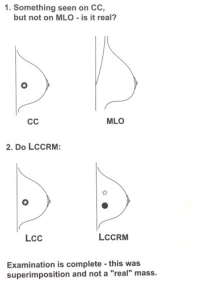

MAMMOGRAPHY EDUCATORS

73

Roll View For Lesion Location

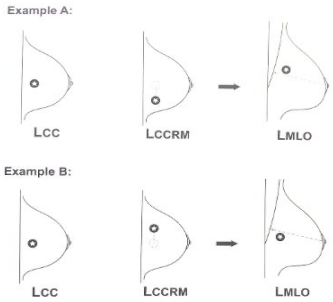

MAMMOGRAPHY EDUCATORS

74

Imaging of Augmented Breasts

- CCs views of each breast with implants in place
- MLO views of each breast with implants in place
- CCID views of each breast with implant displaced
- MLOID views of each breast

MAMMOGRAPHY EDUCATORS

75

Imaging of Augmented Breasts

- CCID views of each breast with implant displaced
- MLOID views of each breast with implant displaced

MAMMOGRAPHY EDUCATORS

76

Imaging of Augmented Breasts

- Full implant views should be done with only enough compression to immobilize the breast to prevent motion unsharpness
- ID views (depending on implant mobility) can be performed with taut compression.

MAMMOGRAPHY EDUCATORS

77

ID – Implant Displaced

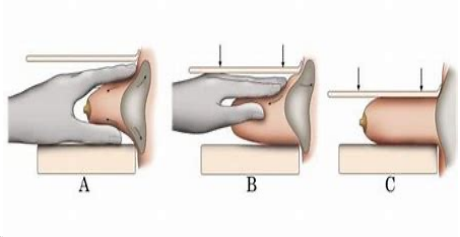

Ref:

MAMMOGRAPHY EDUCATORS

78

Imaging of Augmented Breasts

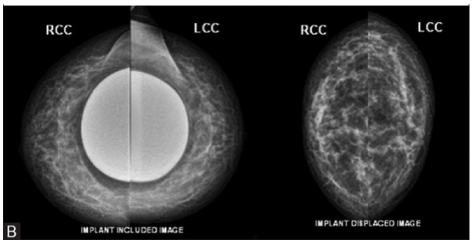

MAMMOGRAPHY EDUCATORS

79

Conclusion

- Additional views are helping in identifying true location of areas of concern
- They are used for diagnostic workups
- Can provide valuable information to aid in diagnosis of breast cancer

MAMMOGRAPHY EDUCATORS

80

References

Miller, L. C., RTRM. (2015). *Mammography Positioning Guidebook*. CA: Mammography Educators.

Miller, L. C., R.R.(R)(M)(ARRT), Lehmann, T. L., B.S. R.T. (R)(M)(ARRT). (2020). *Image Quality & Positioning Problem-Solving for Breast Imagers: Meeting EQUIP Standards* (1st ed.). San Diego, California: Mammography Educators.

Long, S. M., Miller, L. C., Botsco, M. A., & Martin, L. L. (2010). *Handbook of Mammography* (5th ed.). Edmonton: Mammography Consulting Services.

MAMMOGRAPHY EDUCATORS

81

Thank you from your Mammography Educators Team!

To learn more go to:
www.mammographyeducators.com
619-663-8269
And like us on

MAMMOGRAPHY EDUCATORS

82